

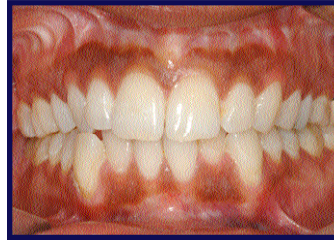
Pretreatment/Case Planning Photo Checklist

To assist you in treatment planning, we need your insights through photographs. We have listed a number of views necessary to give you our best.



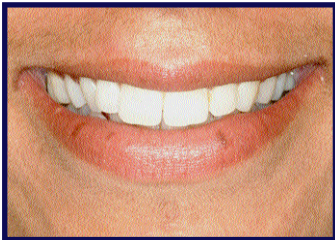
1. Full face smiling

- have patient sit upright or stand
- pictures should be taken at a right angle, with patient's head straight
- smile should be natural not forced



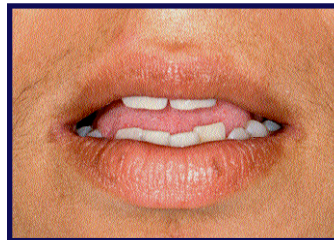6. Maximum Intercuspation with retractors

- shows front-to-back progression



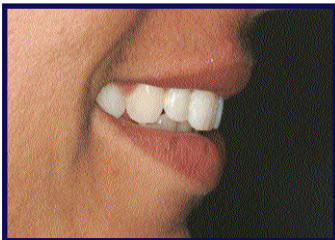2. Smile - without retractors

- frame the image just inside nose-to chin; captures relationship of upper smile line to lower lip line



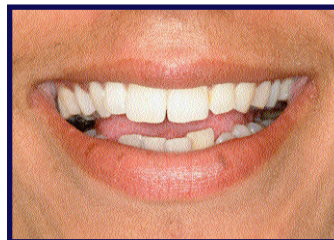7. Rest position

- to show display relationship of incisal plane of lower teeth to lower lip
- very important image to evaluate wear cases



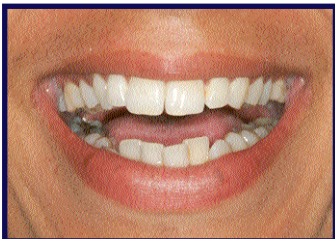
3. Profile - close-up

- shows the upper incisal edge position to inner vermillion border of lower lip



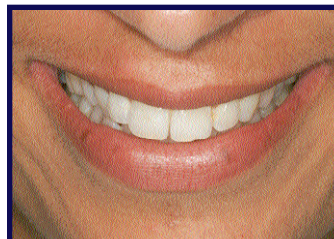
8. Smile - teeth apart

- displays the silhouette of upper and lower incisal plane



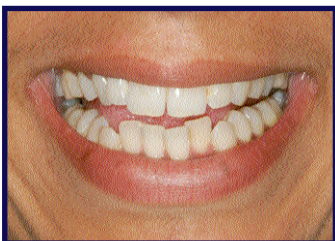
4. High smile line

- have patient laugh or smile as high as possible to determine maximum tooth display
- provides information on embrasures, symmetry of gingival heights, & information for margin placement



9. Smile - head tipped down slightly (with patient sitting, shoot down from above)

- shows the relationship of arch form to lower lip
- especially good for reviewing anterior pontics



5. "E" position

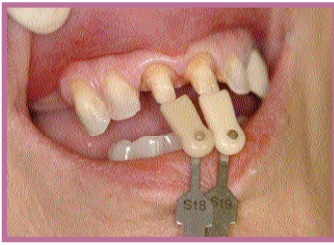
- shows relationship of upper incisors to upper lip
- age appropriate tooth wear may be evaluated



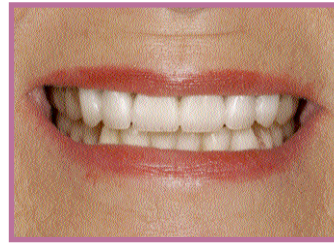In cases with severe wear, request an old photo from high school, college, or a wedding.

Photo Checklist for Lab Communication of Anterior Cases

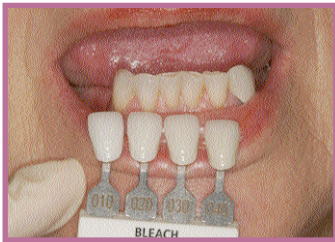For lab communication of anterior cases we recommend the following images of provisionals:



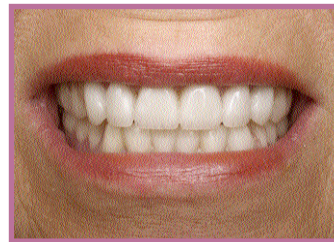
- 1. Stump shades**
- for all-ceramic restorations



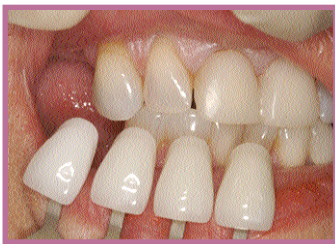- 6. Provisionals - nose-to-chin, relaxed smile**
- shows relationship of upper smile line to lower lip line



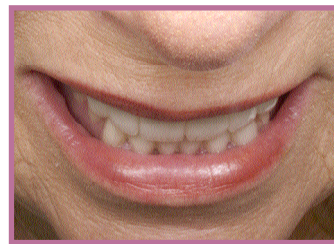- 2. Closest matching shade guide next to teeth -**
- guide numbers visible



- 7. Provisionals - nose-to-chin, high smile**
- shows visible gingival areas



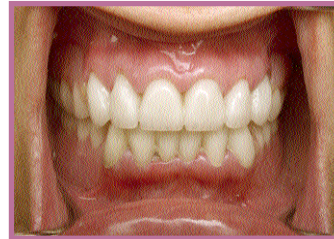- 3. Close-up of adjacent teeth**
- to show surface texture and luster



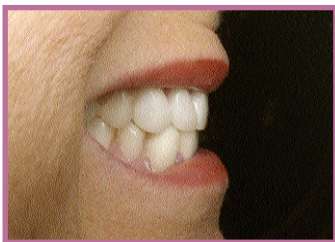
- 8. Provisionals - smile head tipped down slightly** (with patient sitting, shoot down from above)
- shows the relationship of arch form to lower lip
 - especially good for reviewing anterior pontics



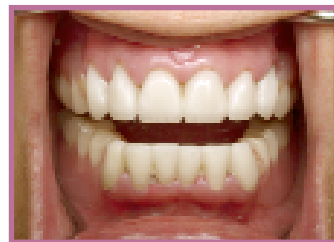
- 4. Provisionals - full face smiling**
- have patient sit upright or stand
 - pictures should be taken at a right angle, with patient's head straight
 - natural smile, not forced



- 9. Provisionals - close-up, lips retracted with teeth in maximum intercuspation**
- shows front-to-back progression



- 5. Provisionals - profile, close-up**
- shows the upper incisal edge position to inner vermillion border of lower lip



- 10. Provisionals - close-up, lips retracted with teeth apart**
- shows incisal silhouette